

Case Report

Systemic Venous Return Abnormality Associated with An Abnormality of Total Pulmonary Venous Return

Mourad Abdelbaki¹, Wahib Bourida², A. Boureghda³, Roudoci¹

¹cardiology department EHS Laghouat (ALGERIA)

²cardiac surgery department EHS Draa Benkhadda (ALGERIA)

³cardiology department CHU de Blida. (ALGERIA).

Received: 05 September, 2023

Accepted: 08 October, 2023

Published: 14 October 2023

Abstract:

This is a 9-year-old child hospitalized for an intraoperative partial venous return anomaly and after an exploration we found a complex congenital cardiac pathology such as an anomaly of total venous return associated with an anomaly of systemic venous return which is mainly seen at early ages Mots-clés Anomalie de retour veineux systémique, Anomalie de retour veineux pulmonaire total, Collecteur Confluence pulmonaire, Urgence néonatale

Keywords: Systemic venous return anomaly, Total pulmonary venous return anomaly, Collector, Pulmonary confluence, Neonatal emergency.

Introduction

Total venous return anomalies are severe malformations which generally progress to death in infancy in the absence of surgery. In this anomaly, all pulmonary veins drain not into the left atrium, but into the right atrium or one of the afferent vessels, superior vena cava or innominate venous trunk. The atrial septal defect is necessarily associated with this vessel, as it is the only one that ensures systemic circulation. The incidence of total pulmonary venous return anomaly is 4 per 100,000 births. Its prevalence is 0.3% (1.24-0.40) of all congenital heart defects. 50% die by 3 months of age, and over 80% by 1 year (1).

Observation

A. Meriem, aged 09 years and 7 months, 2nd of 3 siblings, from Annaba. Admitted for management of partial pulmonary venous return anomaly.

Medical history of repeated respiratory infections, physiological history of walking at age 4 and family history of two early abortions.

History of illness: the patient had been poorly followed since the age of 6 months for a CIA diagnosed on cardiac ultrasound. A partial pulmonary venous return anomaly was diagnosed at the age of 9.

Clinical examination on admission revealed a conscious, cooperative child with good mucocutaneous coloring and limited weight-bearing development, weighing 20 kg and measuring 1.13 m in height.

On cardiovascular examination, the patient was at NHYA stage II with an oxygen saturation of 94%, a mesosternal systolic murmur was noted, with no signs of PAH or cardiac decompensation. Femoral pulses were present. The rest of the clinical examination was normal.

The ECG showed a regular sinus rhythm of 83 beats/min, incomplete right bundle branch block, signs of right atrial hypertrophy and right ventricular hypertrophy. fig.1

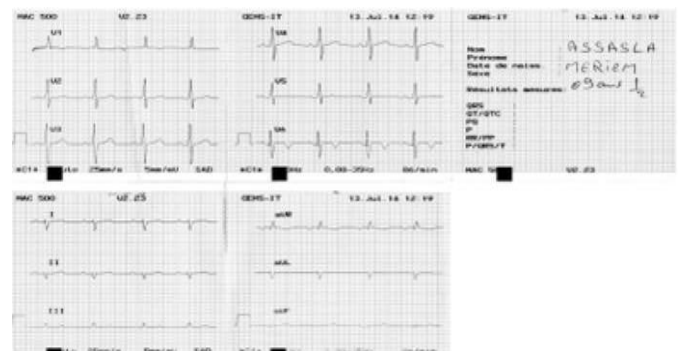

Figure.1

The chest X-ray showed an increase in the cardiothoracic index, a protrusion of the right upper arch, the right middle arch and the left lower arch. A supra-diaphragmatic point and an increase in the pulmonary vascular tract. fig.2

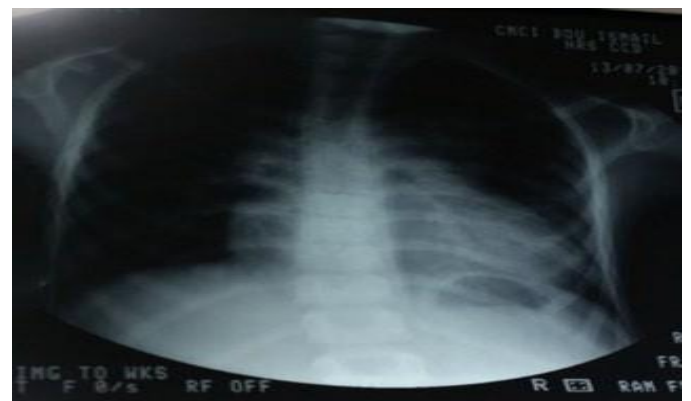

Figure.2

Cardiac ultrasonography revealed a large AIC with a left-to-right shunt, interruption of the inferior vena cava with a superior vena cava azygos return, a partial pulmonary venous return of the superior pulmonary vein type, which emptied into the superior vena cava, and a systemic pulmonary arterial pressure of 46 mm Hg.

Cardiac catheterization fig.3

- Path
 - VFD □ VCI gauche □ héli azygos □ TVI □ VCS □ OG □ VG
 - APT non crossed
- Angiography
 - Angiography LV
 - LV good function without obstruction
 - Aorta of good caliber Pressure
 - Aorta 120/50/78
 - Pulmonary pressures not measured invasively

Conclusion

- Wide CIA (bone)
- Hemi azygos continuity of left VCI into TVI

CNAS
CMCI/EHS DE BOU-ISMAL
WILAYA DE TIPAZA
SERVICE DE CARDIOLOGIE PEDIATRIQUE

PROTOCOLE OPERATOIRE DE CATHETERISME

Nom : ASSASLA
Prénom : Meriem
Date de naissance : 20/01/2005
Date de l'intervention : 14/07/2014

Opérateurs : Dr. TOUATI / Dr. SMAIL
Aide :
Anesthésiste : Melle. OUDINI
Diagnostic : - CIA (os) large.

Trajet de sonde :

VFD → VCI → Retour Azygo cave sup → VCS → OD
VG ← OG

APT non traversés

Angiographies
Angio VG :

- VG de bonne fonction sans obstacle.
- Aorte de bon calibre.

Pressions :

- Ao : 120/50/78 mmHg.
- Pressions pulmonaires non mesurés de façon invasive.

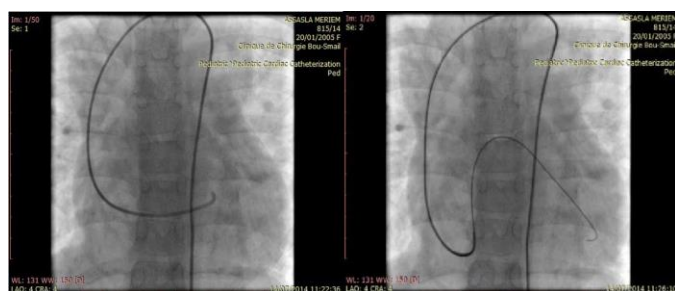Conclusion :

- CIA (os) large.
- Retour azygo cave supérieur.

Dr TOUATI



Figure.3



Summary 1

The hemi azygos continuum of the left inferior vena cava presents numerous anatomical variations in relation to the complexity of their embryonic development:

- Posterior cardinal
- Subcardinal
- Supracardinal

Any association is possible, making the spectrum of potential variations very wide. Although most are asymptomatic, they are

important for the surgeon to know.

Intraoperative exploration

After a right atriotomy parallel to the atrioventricular groove, a large superior atrial septal defect was found at the origin of the superior vena cava outlet. The absence of right and left pulmonary vein orifices in the left atrium suggests a diagnosis of total pulmonary venous return anomaly.

Dissection of the right pulmonary veins, which emptied into a collector behind the left atrium, was followed by dissection of the left pulmonary veins, revealing a 20 to 30 mm- diameter collector which emptied into the innominate venous trunk, which was monitored by a lake.

All in all, the diagnosis of a total supra-cardiac pulmonary venous return anomaly associated with a systemic venous return anomaly such as interruption of the inferior vena cava with hemi azygos cava return was confirmed.

Summary 2

1. Total supracardiac pulmonary venous return anomalies account for 50% of venous return anomalies, which arise in either the innominate venous trunk, superior vena cava or azygos vena. The total cardiac pulmonary venous return anomaly represents 25% of total pulmonary venous return anomalies, which drain either into the coronary sinus or the right atrium. Intracardiac total pulmonary venous return anomaly represents the final 20% of total pulmonary venous return anomalies, which are either in the portal vein or one of the afferent vessels. However, a combination of two of these anomalies can occur, and is referred to as mixed total pulmonary venous return anomaly (2) fig.5

Procedure

Incision of the posterior wall of the left atrium towards the left auricle, opening of the posterior pulmonary venous impingement then anastomosis between the posterior pulmonary venous impingement and the posterior wall of the left atrium, followed by closure of the atrial septal defect by pericardial patch, then closure of the right atriotomy. Ligation of the collector was performed after clamp testing following cessation of extracorporeal circulation.

Summary

Two technical points are very important.

1. Perfect recognition of the anatomy by dissection of the origins of the four pulmonary veins and the collector.
2. Perform a wide anastomosis between the collector and the adjacent left atrium. Post-operative follow-up

Postoperative recovery was straightforward, with hemodynamic stability and medical treatment including adrenaline, diuretics, antibiotics, morphine, analgesics and corticoids. Cardiac ultrasound revealed a well-functioning right and left ventricle, an unobstructed pulmonary venous return in the left atrium and a systemic pulmonary pressure of 45 mm Hg fig.4

Postoperative stay was 10 days. Discharge cardiac ultrasound revealed a tight patch of atrial septal defect with moderate

tricuspid insufficiency and a pulmonary artery pressure of 42 mm Hg. unobstructed pulmonary venous return to the left atrium. The patient was discharged at 10 days post-op, with follow-up appointments at 1 month, 3 months, 6 months and 1 year.

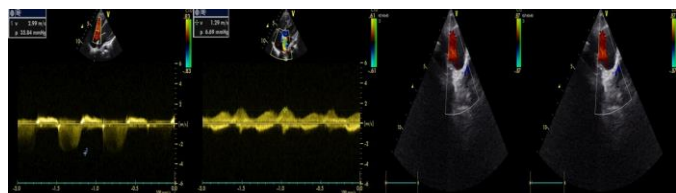


Figure.4
Cardiac angioscan fig.5

Demonstration of the interruption of the inferior vena cava with a left inferior vena cava and a hemiazygos superior vena cava return. The anastomosis between the pulmonary vein collector and the left atrium is wide, with no stenosis. Ligation site of the downstream collector

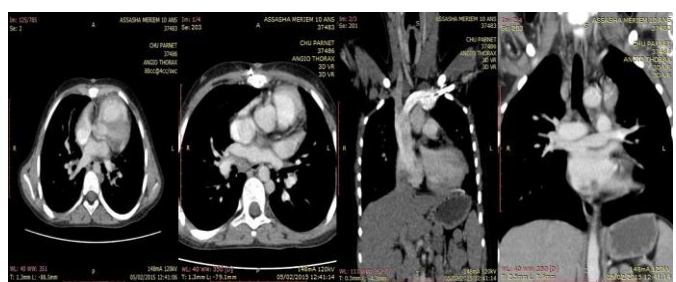
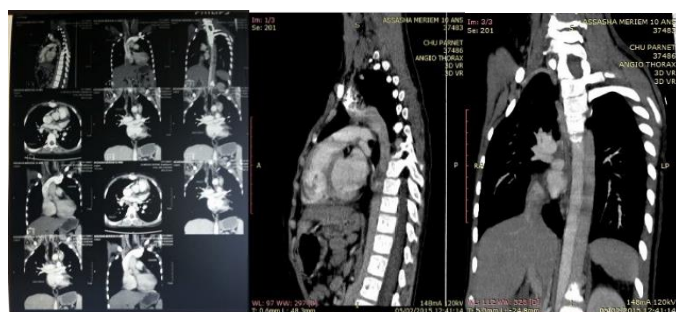


Fig 5
Summary

In contrast to partial pulmonary venous return anomalies, total pulmonary venous return anomalies are severe malformations which generally progress to death during infancy in the absence of surgery. In this anomaly, all the pulmonary veins drain not into the left atrium but into the right atrium or one of the afferent vessels: superior vena cava or innominate venous trunk, atrial septal defect is necessarily associated with it, as it is the only one to ensure systemic circulation: 4-6 per 100,000 births, i.e. 1 - 3% of all congenital heart defects, 50% die by the age of 3 months, and over 80% by the age of 1 year(3,4). It is the 4th most common cyanogenic congenital heart disease to be operated on in the first year of life.

Three factors determine the impact of the malformation: 1-The size of the atrial septal defect conditions the systemic circulation (RASHKIND atrioseptostomy is sometimes necessary); 2-Obstruction of extrinsic or intrinsic pulmonary venous return, leading to an emergency (total blocked pulmonary venous return anomaly); 3-The state of the

pulmonary vascular bed (venous obstruction, huge left-right shunt).


Depending on the early onset and intensity of symptoms, 3 types can be distinguished:

- 1- Neonatal pulmonary edema (most severe form, small heart, major obstruction to pulmonary venous return, anomaly of blocked total pulmonary venous return (this pathway mainly infracardiac). Infant heart failure (cardiomegaly, pulmonary arterial hypertension, anomaly of total pulmonary venous return above the diaphragm and small atrial septal defect).
- 2- Early childhood forms: These are the forms that evolve spontaneously without Heart failure. The RVPAT is supradiaphragmatic with a large atrial septal defect heart and moderate pulmonary hypertension.
- 3- Older children and adolescents: These forms are rare. They have two aspects: a neglected total pulmonary venous return anomaly that has survived in the absence of surgical repair, but develops more or less torpid obstructive pulmonary hypertension; the large-amplitude atrial septal shunt, but without significant pulmonary hypertension. The prognosis after surgery is better (symptoms are those of a large, high-flow atrial septal defect). Only one case has been published in the British Heart Journal, in a ten-year-old child, with an excellent outcome (5).

References

1. Liu Y et al. Int J Epidemiol. 2019.
2. Darling RC, Rothney WB, Craig JM. Total pulmonary venous drainage into the right side of the heart: report of 17 autopsied cases not associated with other major cardiovascular anomalies. Lab Invest 1957;6:44.
3. Keith et al. Am J Med 1954 ;16 :23-38.
4. Burroughs & Edwards, Am Heart J 1960;59:913-931.
5. Desmond F. Duff, Michael R. Nihill, Thomas A. Vargo, and Denton A. Cooley from The Section of Cardiology, Department of Pediatrics, Baylor College of Medicine, and Texas Children's Hospital; and The Surgical Section, Texas Heart Institute, Houston, Texas, U.S.A. British Heart Journal, 1975, 37, 1093-1096.

Copyright (c) 2023 The copyright to the submitted manuscript is held by the Author, who grants the Clinical Medicine and Health Research Journal a nonexclusive license to use, reproduce, and distribute the work, including for commercial purposes.

 This work is licensed under a [Creative Commons Attribution 4.0 International License](https://creativecommons.org/licenses/by/4.0/)