

Review Article

A Literature Review on Effects of Positioning and Early Ambulation on Coronary Angiography Complication

Sulaiman Abubakar Sulaiman¹, Dr. Shahiduz Zafar²

¹BPT Student Dept of Physiotherapy Smas Galgotias University Greater Noida U.P

²PhD, M.PT Professor Dept. of Physiotherapy Galgotias University

Received: 15 August, 2023

Accepted: 15 September, 2023

Published: 21 September 2023

Abstract:

Introduction: The study was carried out to get a greater awareness of the impact of early ambulation and positioning on coronary angiography complications. And to build an evidence study on what other research said.

Objectives: The objective of this study is to review the effect of changing position and early ambulation on coronary angiography complications.

Methods: I used search engines were Identified 700 articles, I excluded 500, then screened total of 200 articles, 150 articles are not my concern, I included 36 articles in this research

Result: According to the various research early ambulation and early position is safe after coronary angiography because it is effective way to minimize the risk of back pain and has no linkage in increasing risk of vascular complications like bleeding or hematoma.

Keywords: Coronary angiography, early positioning, vascular complications and early positioning.

Introduction

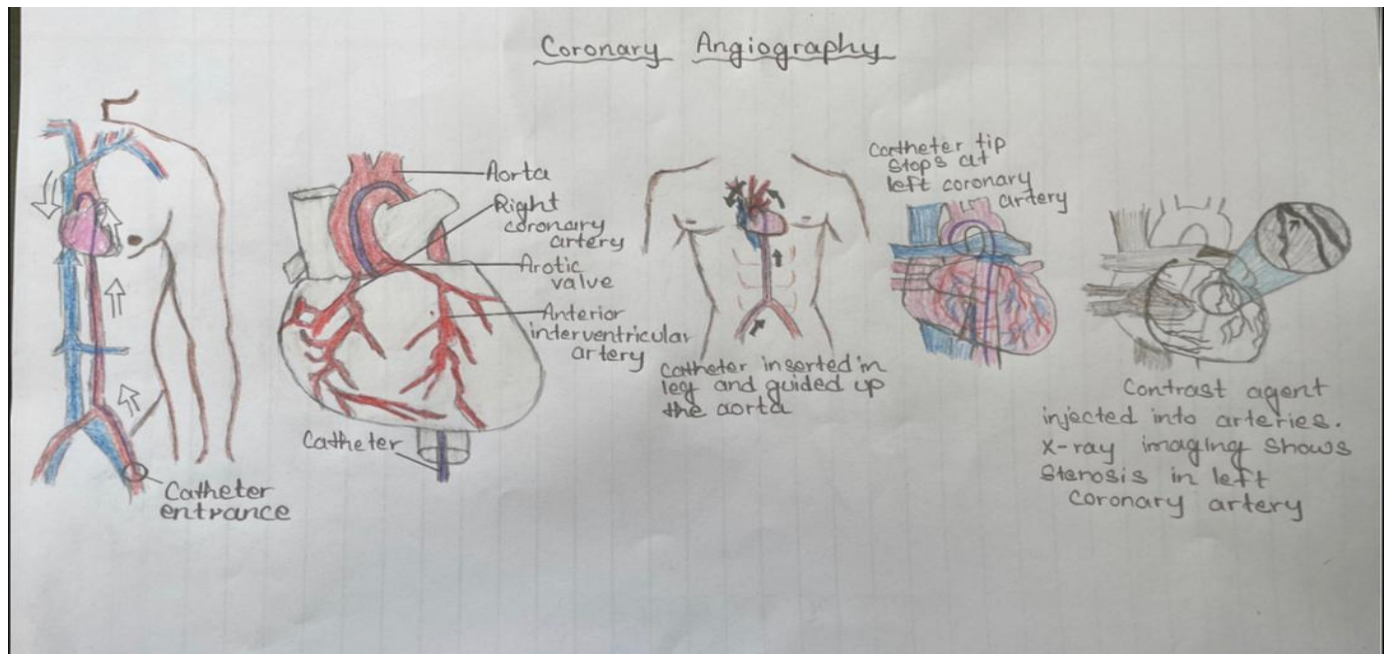
Coronary Angiography

Coronary angiography is a common diagnostic procedure used to evaluate and assess heart conditions such as coronary artery and valvular disease. [1]. Although it can be done via the brachial, radial or femoral arteries [2].

Percutaneous femoral methods are used for the majority of cardiac catheterizations [3]. However, vascular issues such as bleeding, hematoma, back discomfort, and urine retention are severe consequences after cardiac catheterization that might occur as a result of a femoral artery trauma [4]. As a result of these risks, it is necessary for patients to stay in bed in a supine posture for 6 hour to 1 day following the treatment, with the afflicted leg immobilized, to prevent groin bleeding, which occurs in few patients. [5]

Strict immobility and hospitalisation in the supine position are recommended in patients to limit the risk of vascular problems at the groin location [6]. It's also necessary to apply hard pressure above the puncture site, either manually or mechanically. After sheath removal, patients must also be kept in a recumbent position for an extensive duration of time and have their affected leg immovable [7]. To avoid vascular

problems, the affected leg is immovable for 2–24 hours after the treatment [8]. In the tissue of both the upper thigh, hemorrhage and internal bleeding are frequent, and they usually go away after a few days [9]. As a result, it's critical to find safe and practical ways to improve patient convenient without increasing the comorbidities of vascular problems including hematoma and bleeding [7]. Back pain and bladder discomfort are the most common complaints from individuals who have been in bed for an extended period of time [6]. Enduring such long bed rest in supine position, meanwhile it is challenging for numerous patients which this is linked with difficult for them. This has been proven in investigations that this sort of positioning is based on history instead of on evidence [10]. The most unwanted hospital administration is time consuming that is of the essence for these patients in postoperative, lie down flat to avoid back pain and urine retention [11]. Early ambulation and changing positions in bed, as well as shortening the time of bed rest, may reduce patient pain, decreasing current nursing labour, minimizing in-hospital duration stay, and access to fulfil self-care requirements like feeding, drinking, and so on [12]. Early ambulation can ameliorate these discomforts produced by prolonged bed rest without such a major increase in post-angiography issues, and its efficiency had been investigated in numerous trials [6].



i. Early Ambulation

Early ambulation following cardiac catheterization is linked to improved comfort and well-being, as well as a reduction in fatigue, without increasing bleeding and hematoma [13].

ii. Early Positioning

Early positioning in patient after coronary angiography is essential for improving the patient’s recovery, because of the risk of back pain patient must remain in bed after a femoral route. The treatment a lot of patients are needed to be in bed for at least 1 day [14].

iii. Complications

Side effects that are typical in invasive procedures, such as atrial thrombosis and blood lost, might occur in diagnostic and sub-treatment procedures performed through vessels [2].

Review of Literature

1 Coronary Arteries

The coronary arteries are arterial channels that supply oxygenated blood to the cardiac muscles. The heart is like other body organs, need oxygen to operate effectively [15]. Moreover, catheterization was introduced by Andre Cournand and Dickinson Richard and was performed by Werner Forssmann [16].

In recent years, coronary angiography has changed greatly, allowing more than thousands of patients with atherosclerosis-related coronary artery disease to profit from heart bypass operations and PCI, including stenting. The patient is sedated and anaesthetized at the point of peripheral artery entry for 15–30 minutes during the diagnostic procedure. For a variety of reasons, despite the advancing of other imaging machine such as computed tomography (CT) and magnetic resonance imaging (MRI), specialised, catheter-based X-ray coronary angiography is the most regularly used procedure for accurate imaging of the complete coronary branch [16].

a. Functions coronary arteries

Arteries transport blood into cardiac muscle and to operate this heart muscle requires oxygen-rich in blood.

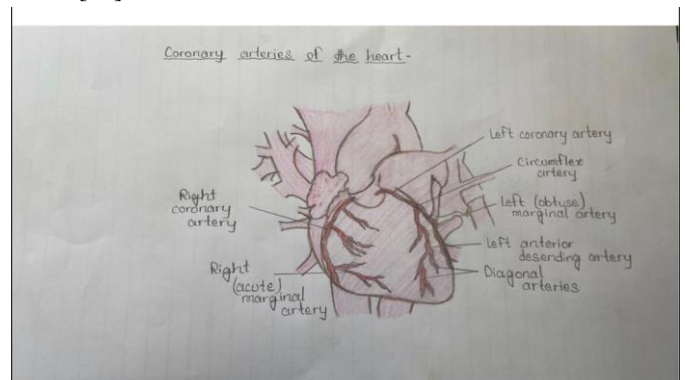
Similarly, It is necessary to transfer oxygen-depleted blood. Coronary arteries encircle the heart on all sides. Little branches penetrate the heart muscle to send blood to it.

b. What are division of coronary arteries?

It is divided into right and left coronary arteries.

Coronary artery to, the right (RCA). The right coronary artery maintains heartbeat by supplying blood to the right atrium and right ventricle, and the Sino atrial (SA) and atrio-ventricular nodes (AV). It was separated further into smaller trees, such as the right posterior descending and acutely border arteries. The right coronary artery helps provide blood to the cardiac septum with the support of the left anterior descending artery.

The coronary artery on the left side is the left largest coronary artery (LMCA). The largest left coronary artery provide blood into the left portion of the cardiac tissues, the left ventricle and left atrium. The left major coronary artery is divided into segments. The left anterior descending artery (LAD) is a branching of the left coronary artery that provide blood to the posterior chamber of the heart. The circumflex artery runs and encircled heart tissue and is a component of the left rear of the heart. [19].



C. Coronary artery disease

Coronary artery disease is commonly called as coronary heart disease is the top leading of death in human group as a result of factors such as environment, genetic and lifestyle may increase

the occurrence of cardiovascular disease. Due to disrupting of blood for long period of time, heart most work harder which may lead to failure of heart or arrhythmia, the affected arteries may become completely clogged or prone to clotting, leading to a heart attack. [20].

ii. Angiography

A blockage in blood artery, aneurysm, heart disease with structural abnormalities, or valvular disease can all be diagnosed and treated by angiography [21].

An angiogram is a test that uses X-rays, computerised tomography angiography, or magnetic resonance angiography to visualise blood flow via arteries and veins, or via the heart.

The contrast dye is inserted to the blood, to causes the blood arteries to appear on the image by lighting up on the scan wherever it flows.

Contrast dye passes through the blood, revealing the form of the blood vessel on an X-ray or MRI image. If the shape of the blood flow narrows in one spot, this indicates that the artery is partially blocked. If the artery's form widens in one spot, it has an aneurysm.

Traditional angiography sends contrast dye directly to the region of the body being examined through a small tube called a catheter.

A weakly radioactive contrast dye permits the heart to show up on a fluoroscope, creating an X-ray video that presents a moving image of blood flow through the heart in radionuclide angiography.

In computerized tomography angiography and magnetic resonance angiography, the contrast dye is injected into arm and circulates through the body. Both produce 3-D images of the blood vessels and are minimally invasive procedures.

After the scan, the contrast dye exits the body through urine or faeces [21].

Figure

a. Indications and contraindications

i. Indications

1. Coronary artery disease
2. Angina
3. Ischemic heart Disease
4. Onset of unexplained congested heart failure
5. Chest injury

ii. Contraindication

The cardiac catheterization technique has no definite clear contraindications. The most contraindications are relative, based on the technique indication and the patient's complications. Alternative means of imaging and verification can be operate to address the hospital question when the probability of complications is projected to be greater than what is regarded welcome for the surgery. Experienced operators most adjusted the technique process to provide the great possible results to the patient while trying to minimize danger. The doctor must have a proper knowledge of the hospital question that is need to be answered before designing this operation [22].

iii. Complication After Angiogram

1. Vascular Complications

563

i. Hematoma and Bleeding

Collection of clotted blood may form in the access site of of artery. Hematoma is major complication of angiogram when blood transfusion or long hospitalization occur [23].

Bleeding is a major complication because a catheter is inserted in the puncture site, this may lead to bleeding, and to minimize bleeding external pressure will be applied on the site to stop it [24].

ii. Bacteremia/ sepsis

Bacteria can enter the bloodstream through fibroids that are degenerating. Blood cultures can be used to diagnose Bacteremia and sepsis (a more serious type). Fever and other infection-related symptoms are usually present for at least 24 hours. Only one death due to sepsis has been reported in over 10,000 individuals, and the circumstances surrounding that case were unusual [24].

iii. Respiratory insufficiency

This can result for numerous of reasons, includes Congestive heart failure with swollen lungs and other lung disorders, prompt analysis of patient's situation is needed and therapeutic management should be given [25].

2. Urinary Retention

Urinary retention has been noticed as common issues in patients who have had angiography. Because bladder catheterization projected the chances of urinary retention, it is suitable to depend on non-invasive techniques to urinate completely.

Urinary retention can be temporary, but if left untreated, it can harm the urinary system [26].

3. Allergic reaction

Following anaesthesia, it was discovered that some drugs, such lidocaine, cause dermatologic reactions as a result of drug preparation [27].

4. Back Pain

Complete bed rest after coronary angiography may leads to discomfort or lifetime back pain, therapist intervention are designed to decrease patient's discomfort and pain due to prolonged bed rest. The shorter the bed rest the more the increase in well-being, the early the discharge of patient and Cost reduction.

Medication can be given to ease loss manpower and reduce pain. [28].

1 Masoumeh Neishabouri et al (2020) In a trial including 120 participants, the demographic data for the first four hours were collected for a complication checklist. The control group remained supine in bed for a full six hours following angiography, while the intervention group changed positions hourly.

The control subjects had more back pain and discomfort than the treatment group, which changed positions after 6 hours and had no bleeding, hematoma, or other complications.

As a result, shifting positions and early mobilization are both safe and free of vascular complications, and they can help avoid or alleviate back discomfort [29].

2-Ali Akbar et al (2015) In the post coronary angiography to

diminished the occurrence of all complications the patient most not move from Supine position in bed for at least 4 to 24 hours, In a study design to examine the effects of change in position and An early ambulation on urinary retention in post cardiac catheterization.

The trial of 35 different group of patient was made, where first group were not allowed to move, the 2nd one position allowed to change position, and the second to the last group are ambulated early, the last group are allowed to change position. The result shows that zero of the group was present with vascular complication but the urinary retention risk is projected more, although there is high pain intensity of 4 to 6 hours. Their findings is says that it's safe to change position and early ambulation after coronary angiography [30].

3- Chair s.y et al (2003) the study was made to check intensity of back pain in post coronary angiography and to analyse the effects of positioning change in patients. Many patients are needed to remained resting in bed for at least 24hours after operation, the effects of decreasing this bed rest time is already been under examination.

Two group was separated in which one is under control and others change position after 7 hours, the study the patient under control have high intensity of back pain. Therefore, this is secured to change position in post coronary angiography [28].

4- Yilmaz E, Gurgun C, (2007) The goal of the study was to see how placing a sandbag on the femoral entrance site after a cardiac invasive operation and modifying the patients' positioning in bed affected the frequency of vascular problems and the intensity of back pain following the treatment. This clinical trial involved 169 patients were allotted to one of five groups at random. After the procedure, Group one patients received a 4.5 kilograms sandbag for half an hour and Group two patients received a 2.3 kg sandbag for two hours on the femoral access site. Starting with the second hour, the body positions of Group one and two patients were modified hourly. After catheterization, Group three patients received a 4.5 kg sandbag for half an hour and Group four patients received a 2.3 kilograms sandbag for 2 hours on the femoral access site, and their body postures was not modified. Patients in Group five maintained in a supine position without switching positions and were not given a sandbag. **The result shows** the group with the sandbag was analyses to the group without the sandbag, the complication of vascular problems is not substantially different. Patients with back pain reported it more frequently when their positions were not modified or their beds' heads were not lifted. Therefore, use of a sandbag did not reduce the risk of vascular problems following the treatment. To improve the patient's comfort and reduce back discomfort, the position of patient should be adjusted; the head of the bed shall be lifted 30 to 45 degrees [31].

5- Steffenino et al. (2006) The purpose is to track vascular access complications in these patients with or and absent closure machines as a starting point for future improvement. Methods: A four-month observational research of all vascular accessing concerns in sequential catheterization patients overseen by a nurse. The radial and femoral approach have been

used in (14%) and (83%) of the 564 sessions, accordingly, with a closing device applied in 136 of the latter. In 9.6% of cases, a hematoma (of every size) was separated and simple. In 1.2 percent of participants, more serious problems (haemoglobin reduction > 2 g, requirement for transfusion of blood, or vascular surgery) developed, namely in very few of the radial access operations and 0.4 percent and 2.4 percent of femoral clinical coronary techniques, correspondingly. The activated coagulation duration was ($p = 0.004$) following problematic ($n = 40$) vs simple ($n = 172$) transfemoral procedures, but the adoption of closing equipment was equal.

Finally, the patients had less severe vascular access issues than other studies, and radial cprocedures were generally unaffected. In these patients, strong anticoagulant was linked to more problems, although closure devices were also not. A policy change will be explored, which includes using radial access wherever feasible and using a less harsh anticoagulant regimen for transfemoral interventions [32].

6 -Rosenstein et al (2004) in patients with coronary artery disease, heart catheterization is often used for diagnostic and therapeutic purposes. To minimize groin problems after a femoral approach, 4hour to 6hour of post-procedure bed rest is indicated. This prolonged rigorous bed rest is linked to patient suffering and higher medical expenditures, and it prevents referred outpatients from being treated more efficiently in catheterization laboratories. As a result, the applied a basic clinical strategy to the test in order to select limited risk individuals who would improve from moving within 2 hours of sheath removal. 98 outpatients were divided into two groups depending on difficulty getting artery access, appearance of leaking or hematoma after finishing manual compression ($t=1.5$ to 2hours; $n=74$) or conventional movement ($t=4$ to 5 hours; $n=24$). Bleeding was the most common side effect, with one early moved and three conventionally moved patients experiencing it when discharge from hospital, and 11 early moved and 6 conventionally moved patients experiencing it at 1-week follow-up. There have been no significant hematomas, retroperitoneal hemorrhage, or transfusions of blood in any of the patients. Most outpatients who have an optional diagnostic catheterization may benefit to move safely based on simple clinical factors [12].

7- Sobolev et al (2015) Background: Regardless of the tendency towards gaining circulatory access through the radial rather than the femoral artery, femur artery cannulation occurs commonly in cardiac cath". Preventing vascular problems associated with femur artery cannulation is critical since they can be fatal.

Method: Controlled Trials was used to conduct a comprehensive literature search. Comprehensive abstracts from adequate care, interventional radiology, vascular surgery, and cardiology over the previous five years were also studied. Two reviewers uncovered randomised, a series of controlled studies comparing ultrasonography guidance to traditional navigation probing procedures for femoral artery angiography (with fluoroscopy or without fluoroscopy). The following information was gathered: sample design, research size,

operation and patient demographics, infection rates, first-pass effectiveness, operation duration, and number of tests.

Result: The review covered four studies totalling 1422 patients, including 703 patients in the examination category and 719 participants in the ultrasonic guided group. Ultrasound guiding for femoral artery catheterization was related with a 50 per cent drop in total complications, including hematoma and accidental venepuncture, when compared to standard approaches.

Conclusion: For femoral artery angiography, real-time 2 Dimension ultrasound guiding reduces life-threatening vascular complications and increases pass rates of success [33].

8- Hojjat et al (2021) Patients may experience pain and circulatory problems as a result of lengthy immobility after transfemoral cardiac catheterization. The focus of this research was to see how effective the change in position would be at pain reduction and circulatory problems among TFA patients.

In the year 2020, a randomized study was undertaken. A number of 72 qualified patients receiving TFA were randomly chosen and subjected to one of two groups: experimental or control. After angiography, patients in the experimental class were put in a supine position approximately two h, then in a semi-seated posture for four hours, with the bed angle steadily increasing to 45 degrees. The control subjects stayed supine for 6 hours. Before, shortly after, more than 6 hours after angiography, both groups were evaluated for vital signs, groin, lumbar, and leg pain, blood clot, bleeding, and urine retention. Pain was assessed using the vas Scale, hematoma was assessed using the Christiansen scale, haemorrhage was assessed using counting blood gas, and patient self-rating was assessed using patient self-rating to asses urine retention

The result indicates there's no notable change in groin, back and leg pain score among EG and CG, the discomfort in the EG was much projected down than the CG from the two to the six hour just after TFA. Hematoma did not occur in any of the subjects. In terms of bleeding and urine incontinence, there are still no changes that occur in both groups.

The conclusion of their research says positioning patient in a semi-seated position following TFA decreases pain effectively and safely without worsening circulatory problems [34].

9- Theresia Febriana et al (2018) Vascular and subcutaneous bleeding (lesion) as well as back pain might occur as a result of coronary angiography. Adjusting the patient's posture in bed can help alleviate pain that comes with diagnostic cath problems.

Method: the study used a genuine experimental design with a random post intervention placebo group. Simple arbitrary selection was used to select 30 participants, fifteen of whom were allocated randomly to the treatment group and 15 to the control group. The research group was placed in a left and right lateral posture with 150°, 300°, and 450° of head of bed inclination. The level of top of bed inclination was recorded including an arc tool, arterial bleeding was recorded with a glass container, subcutaneous bleeding (hematoma) was measured with a punctured clear plastic with a 5 cm in diameter, and low back pain was measured with the Numerical Pain Rating Scale. Measured ANOVA were used to examine the data..

Positioning had no influence on arterial haemorrhaging or subcutaneous haemorrhaging, and there was no noticeable impact on the prevalence of arterial and subcutaneous blood loss, but it may have a significant effect on lowering back discomfort, according to the findings [35].

10- Parisha Rai et al (2019) Even though the femoral method is a common method of performing coronary angiography, hospitalisation is advised because to the possibility of vascular problems. The purpose of this study was to see how patients' satisfaction, fatigue, and circulatory problems are affected by a position change accompanied by early ambulation in post coronary angiography through femoral approach.

Method: A controlled trial analysis was performed on 80 patients who had undergone coronary angiography (40 in each group). Following 6 hours, patients in the comparison group were placed in a supine posture and ambulated. After angiography, group 1 was held in a supine position for two hours, then in a lateral aspect position for an hour, a supine posture for an hour, and then ambulated until 4 hours. At 2, 4, 6, and 24 hours after angiography, Kolcaba's results were examined using the Overall Satisfaction Survey, Numerical Pain Rating Scale, and Tired Visual Numeric Scale.

Overall fatigue reported mostly by the experimental group was significantly lower than that of the comparison group at 4 and 6 hours after angiography. At the 6th and 24th hours, the experimental group had much less back pain but was more comfortable. The incidence of circulatory problems did not vary significantly between control and experimental groups.

Summary of findings: following coronary angiography by the femoral method, position shift followed by early ambulation is free from side effects because it reduces back discomfort, tiredness, and leads to better health without worsening vascular problems [36].

Heart disease is the leading cause of mortality in the world. [37] As by WHO data, cardiac disorders still responsible for 30.8 % of mortalities, and one person has died from myocardial injury (MI) each 43 seconds[38],[39], which would be expected to be the leading cause of mortality globally through 2030. [40] According to a study conducted in Iran, cardiovascular diseases accounted for 50percent of all deaths every year 79 % of deaths connected to chronic diseases. [41]

There are different diagnostic techniques for evaluating cardiology patients, including catheterization being most frequent radical technique for cardiac disease detection. [39] As in United States, about 2 million people die every year [42], or above 260,000 in Iran experience diagnostic coronary angiography and intervention therapy or even both [43].

Risks in surgical procedures such as fatalities, MI, cerebrovascular accident, myocardial perforate, circulatory expansion, and regional myocardial channel issues were typical in screening and segmental treatment techniques which are performed via veins access. [37], [38], [44] A most common adverse events following angiography include blood, hematoma, and artery, which are produced by vascular issue at the angiography region. [45]

Various studies have reported a frequency of angiography negative impacts ranging from 0.5 % to 13.6 percent. [46]

Patients should be kept in bed to minimize potential adverse effects, and the neurovascular system of the suffering organs should be checked for haemorrhaging and hematoma. [38] With addition to bleeding and blood clot, backache is an inconvenient side effect for the patients. Back discomfort is caused by prolonged immobility [47]

These procedures of catheterization nurses had altered over latest days, resulting in higher comfortability and satisfaction as well as a reduction in post catheterization effects. [48], [49] [50].

Methodology

Aims of Study

This study is purposely aimed to review the effect of positioning and early ambulation on coronary angiography complications.

Objective of The Study

The objective of this study is to review the effect of changing position and early ambulation on post coronary angiography complications. Such as bleeding, hematoma, urinary retention and back pain.

Statement of Problem

A literature review is done in order to provide an overall view of poisoning and early ambulation on coronary angiography complications.

Significance of Study

To build evidence on the effects of positioning and early ambulation on coronary angiography complications

Hypothesis

Changing patient position and early ambulation in post coronary angiography is proved safe and is not accompanied in increasing the risk of complication after coronary angiography.

Inclusion Criteria:

1. Published studies about effect of positioning and early ambulating on coronary angiography complication.
2. A review studies was included only.
3. Articles published between "2000-2022".

Exclusion Criteria:

1. If the studies were not published or not peer reviewed.
2. If studies reviewed a whole discipline, not individual intervention

Result

According to the various research early ambulation and early positioning is safe after coronary angiography because it is effective way to minimize the risk of back pain and has no linkage in increasing risk of vascular complications like bleeding or hematoma

Positioning had no influence on arterial hemorrhaging or subcutaneous hemorrhaging, and there was no noticeable impact on the prevalence of arterial and subcutaneous blood loss, but it may have a significant effect on lowering back discomfort, according to the findings and early ambulation will also reduce the risk of respiratory insufficient and Urinary

retention. following coronary angiography by the femoral method, position shift followed by early ambulation is free from side effects because it reduces back discomfort, tiredness, and leads to better health standard.

Therefore, vascular complications in a study which four groups where divided following of position changing, early ambulation all the groups reported zero hematoma or bleeding, and backpain, this is another evidence that it is safe to move and change patient's position in post coronary angiography and it has nothing in risking vascular complications.

Discussion

Based on numerous studies available, it has been proved that early ambulation of patient is an effective approach in reducing backache and early positioning reduces urinary retention.

It's therefore also discussed in the study of Masoumeh Neishabouri named "effect of changing position and early mobilizing on backache and circulatory side effects in post coronary angiography," when the 2 group where separated in which one group maintained supine position for 6 hours, while intervention group keep changing position hourly. The results shows the control group recorded more back pain intensity than the intervention group.

It was further discuss in the study of **Rosenstein (2004)** to that minimize groin issues after femoral routes changing patient position is effective, they applied clinical research in which 2 group where divided which some are moved while others are not, the record shows that the moved patient a reported more pain only for a discharge day of hospital, while are the patient reported bleeding more.

It was further discussed based on the research done with comprehensive literature search to identify the navigation of femoral artery angiography with or without fluoroscopy, under the gathered information of demographic, recovery information and infection rate.

The result come shows that there is 50% drop of complication in femoral artery catheterization (**Sobolev et al 2015**).

In Hojjat et al (2021) study discussed in his studies that it is confirmed that immobility after TFA is related to increased complication occur, when group divided into two, others are put in semi seated position and bed angle is elevated 45 degree, and later the evaluated base on vital signs, demographic and blood clot. The evidence shows that the complication drops in experimental group than that of patient in control group.

In the study of Parisha et.al (2019) started that the overall fatigue in experiment group was less than that of control group at 4-6 hour and circulatory complication did not vary in both group.

In addition, **Ali Akbar et al (2015)** shows vascular complications in a study which four groups where divided following of position changing, early ambulation all the groups reported zero hematoma or bleeding, this is another evidence that it is safe to move and change patient's position in post coronary angiography and it has nothing in risking vascular complications.

Conclusion

According to the various research early ambulation and early position is safe after coronary angiography because it is effective way to minimize the risk of back pain and has no linkage in increasing risk of circulatory issues like bleeding or hematoma.

Moreover, early positioning and ambulation should be done under the guidance of healthcare practitioner in order to avoid complications after coronary angiography.

Future scope of study: Early ambulation and early positioning safety after coronary angiography may led the advancing of new technological machines that can move and position patients

Conflict of interest

No any interest conflicts recorded in this study

References

1. Popma JJ. Coronary angiography and intravascular ultrasound imaging. In: Zipes DP, Libby P, Bo now RO, Braun Wald E, eds. Braun Wald's heart disease: a textbook of cardiovascular medicine. 7th ed. Philadelphia: Elsevier; 2005. p. 423-455.
2. Woods, S.L., Frolicker, E.S.S., Motzer, S.U., Bridges, E.J., 2005. Cardiac Nursing, 5th ed. Lippincott Williams & Wilkins, Philadelphia.
3. Kasper, D.L., Braun Wald, E., Fauci, A.S., Hauser, S.L., Longo, D.L., Jameson, J.L., 2005. Harrison's principles of internal medicine, 16th ed. McGraw-Hill, New York.
4. Steffenino, G., Dutton, S., Conte, L., Dutto, M., Lice, G., Tomatis, M., Cavallo, S., Cavalla, S., Deltaville, A., Bareli's, G., LaScala, E., 2006. Vascular access complications after cardiac catheterisation: a nurse-led quality assurance program. *European Journal of Cardiovascular Nursing* 5, 31–36.
5. Chair, S.Y., Taylor-Piliae, R.E., Lam, G., Chan, S., 2003. Effect of positioning on back pain after coronary angiography. *Journal of Advanced Nursing* 42, 470–478
6. Rezaei-Adaryani M, Ahmadi F, Asghari-Jafarabadi M. (2009): The effect of changing position and early ambulation after cardiac catheterization on patients' outcomes: a single-blind randomized controlled trial. *J Nurs Stud* 2009; 46 (8): 1047-53. doi:10.1016/j.ijnurstu.02.004.
7. Benson G (2004). Changing patient's position in bed after non-emergency coronary angiography reduced back pain. *Evidence Based Nurse*; 7: 19.
8. Chair SY, Yu M, Choi KC, Wong EML, Sit JWH, Ip WY. (2012), "Effect of early ambulation after trans femoral cardiac catheterization in Hong Kong,," *Anadolu Kardiyol Derg*; 12: 00.00.
9. Carrozza, J. (2012): Complications of Diagnostic Cardiac Catheterization [updated May 2012]. , Available from <http://www.uptodate.com/contents/complications-of-diagnostic-cardiac-catheterization>
10. Fowlow, B., Price, P., Fung, T., 1995. Ambulation after sheath removal: A comparison of 6 and 8 h of bed rest after sheath removal in patients following a PTCA procedure. *Heart Lung* 24 (1), 28–37.
11. Vlasic, W., 2004. An evidence-based approach to reducing bed rest in the invasive cardiology patient population. *Evidence Based Nursing* 7, 100–101.
12. Rosenstein, G., Cafri, C., Weinstein, J.M., Yeroslavtsev, S., Abuful, A., Ilia, R., Fuchs, S., 2004. Simple clinical risk stratification and the safety of ambulation two hours after 6 French diagnostic heart catheterization. *Cath Lab Digest* 12 (5), 22–25.
13. *Journal of Gorgan University of Medical Sciences*, Autumn 2013, Volume 15 issue 3, p7-12 6p.
14. Kelly L. burn, Robert N. Marshall, Gill Scrymgeour. 2015 "early mobilization after femoral approach diagnostic coronary angiography to reduce back pain" 34(4):162-169. Doi:10.1016/j.jradnu.2015.04.008
15. "Coronary Arteries" Texas Heart Institute Retrieved 2019-09-01.
16. Matthias Barton, Johannes Gruntzig, Marc Husmannz (2014). *Ballon Angiography – The Legacy of Andreade Gruntzig*.
17. Fowlow, B., Price, P., Fung, T., 1995. Ambulation after sheath removal: A comparison of 6 and 8 h of bed rest after sheath removal in patients following a PTCA procedure. *Heart Lung* 24 (1), 28–37.
18. .Rolley JX, Salamonson Y, Dennssison CR, Davidson PM. Nursing care practices following a percutaneous coronary intervention results of a survey of Australian and New Zealand cardiovascular nurses. *J Cardiovasc Nurs* 2010; 25 (1): 75-84.
19. John Hopkins Health system, John Hopkins Hospital, John Hopkins university "Anatomy and Function of the coronary arteries" 2022
20. Eisen A, Kornowski R, Vaduganathan M, Lev E, Vaknin-Assa H, Bental T, Orvin K, Brosh D, Rechavia E, Battler A, Assali A. Retroperitoneal bleeding after cardiac catheterization: a 7-year descriptive single-center experience. *Cardiology*. 2013;125(4):217-22.
21. The Johns Hopkins University, The Johns Hopkins Hospital, and Johns Hopkins Health System 2022
22. Sobolev M, Slovut DP, Lee Chang A, Shiloh AL, Eisen LA. Ultrasound-Guided Catheterization of the Femoral Artery: A Systematic Review and Meta-Analysis of Randomized Controlled Trials. *J Invasive Cardiol*. 2015 Jul;27(7):318-23.
23. Standardford heathcare.org " complication of angiography" 2021
24. Mount Nittany Health " Discharge instructions for angiography May 08, 2021
25. Tavakol M, Ashraf S, Brener SJ. Risks and complications of coronary angiography: a comprehensive review. *Glob J Health Sci*. 2012 Jan 01;4(1):65-93.
26. Hansen BS, Sørdeide E, Warland AM, Nilsen OB. Risk factors of postoperative urinary retention in hospitalised patients. *Acta Anaesthesiol Scand* 2011; 55 (5): 545–48. doi: 10.1111/j.1399-6576.2011.02416

27. Feldman, T., Moss, J., Teplinsky, K., et al. (1990). Cardiac catheterization in the patient with history of allergy to local anesthetics. *Cathet Cardiovasc Diagn*, 20 (3), 165-167.
28. Chair SY, Taylor-Piliae RE, Lam G, Chan S. Effect of positioning on back pain after coronary angiography. *J Adv Nurs* 2003; 42 (5): 470–8. doi: 10.1046 /j.1365-2648.2003.02646.x
29. Masoumeh Neishabouri, Neda Haghighi, Tahereh Gilvari, and Sahar Haghighat. Effect of changing position and early mobilization on back pain and vascular side effects in patients after coronary angiography 2019 Dec. doi: 10.4103/JNMS.JNMS_22_18
30. Ali akbar, shahzad mehranfard, naseer behnampour and abdol mohamad kornejad. Effect of positioning and early ambulation on coronary angiography complication-a randomized trial doi: 10.15171 /j2015.013.
31. Yilmaz E, Gürgün C, Dramal A. Minimizing short-term complications in patients who have undergone cardiac invasive procedure: a randomized controlled trial involving position change and sandbag. *Anadolu KardiyolDerg* 2007; 7 (4): 390-6.
32. Steffenino, G., Dutton, S., Conte, L., Dutto, M., Lice, G., Tomatis, M., Cavallo, S., Cavalla, S., Deltaville, A., Bareli's, G., LaScala. Vascular access complications after cardiac catheterization: a nurse-led quality assurance program. *European Journal of Cardiovascular Nursing* doi.10.1016/j.ejcnurse.2005.06.001
33. Sobolev M, Slovut DP, Lee Chang A, Shiloh AL, Eisen LA. Ultrasound-Guided Catheterization of the Femoral Artery: A Systematic Re view and Meta-Analysis of Randomized Controlled Trials. . 2015 Jul;27(7):318-2.
34. Hojjat niknam sarabi, Zahra Farsi, Samaantha Butler, Amir Hosein Pishgooie. Comparison of the effectiveness of position change for patients with Pain and Vascular Complications after transfemoral Coronary angiography: a randomized Clinical trial. 2021 AN 114
35. Theresia Febriana Christ Tyas Utami, Diyah Fatmasari, Mardiyono, Shobirun. Effect Of Positioning On Bleeding Complication And Low Back Pain After Diagnostic Coronary Angiography In Patients With Coronary Heart Disease In An Integrated Heart Care Center In Indonesia. V (4) No. 2 (2018). doi.org/10.33546/bnj.356
36. Parisha Rai, Manju Dhandapani, Shiv Bagga, L Gopichandran, Yash Paul Sharma. Position Change followed by Early Ambulation after Coronary Angiography via Femoral Approach: A Randomized Controlled Trial. 2019; 9(3): 373-378 .doi:10.5958/2349-2996.2019.
37. Larry Jameson J, Fauci AS, Kasper DL, Hauser SL, Longo DL, Loscalzo J. Harrison's Principles of Internal Medicine. 20th ed. New York: McGraw-Hill Education; 2018.
38. Brunner LS. Brunner & Suddarth's Textbook of Medical-Surgical Nursing. 14th ed. New York: Lippincott Williams & Wilkiness; 2018
39. Writing Group Members, Mozaffarian D, Benjamin EJ, Go AS, Arnett DK, Blaha MJ, *et al*. Heart disease and stroke statistics-2016 update: A report from American Heart Association. *Circulation* 2016;133:e38-360
40. Mathers CD, Loncar D. Projections of global mortality and burden of disease from 2002 to 2030. *PLoS Med* 2006;3:e442
41. Sadeghi M, Haghdoost AA, Bahrapour A, Dehghani M. Modeling the burden of cardiovascular diseases in Iran from 2005 to 2025: The impact of demographic changes. *Iran J Public Health* 2017;46:506-16
42. Tadjonfar M, Foji S, Mohesnpour M, Rakshhani M. The effects of guided imagery on patients anxiety undergoing cardiac catheterization. *JSUMS* 2014;20:689-95
43. Farsi Z, Eslami R, Sajjadi A, Afghi E. Comparing the effect of peer education and orientation tour on the hemodynamic indices of patients candidate for coronary angiography. *Med Surg Nurs J* 2016;4:65-72.
44. Shanmugam V, Velu RB, Subramaniyan SR, Hussain SA, Sekar N. Management of Upper Limb arterial injury without angiography- chennaiexperience. *Injury* 2004; 35:61-4
45. Black JM, Hawks JH, keene AM. Medical surgical Nursing: Clinical Management for positive outcomes. 8th ed. United states of America: Elsevier Saunders co; 2009
46. Woods SL, Froelicher, ES, Motzer SA, bridges EJ. *Cardiac Nursing*, New York; wolters Kluwer Health Adis ESP 2011
47. Tavakol M, Ashraf S, Brener SJ. Risks and complications of coronary angiography: A comprehensive review. *Glob J Health Sci* 2012;4:65-93
48. Younessi Heravi MA, Yaghubi M, Joharina S. Effect of change in patient's bed angles on pain after coronary angiography according to vital signals. *J Res Med Sci* 2015;20:937-43.
49. Chair SY, Taylor-Piliae RE, Lam G, Chan S. Effect of positioning on back pain after coronary angiography. *J Adv Nurs* 2003;42:470-8
50. Andersen K, Bregendahl M, Kaestel H, Skriver M, Ravkilde J. Haematoma after coronary angiography and percutaneous coronary intervention via the femoral artery frequency and risk factors. *Eur J Cardiovasc Nurs* 2005;4:123-7

Copyright (c) 2023 The copyright to the submitted manuscript is held by the Author, who grants the Clinical Medicine and Health Research Journal a nonexclusive license to use, reproduce, and distribute the work, including for commercial purposes.



This work is licensed under a [Creative Commons Attribution 4.0 International License](https://creativecommons.org/licenses/by/4.0/)